



## **Evaluation of wound healing potential of aqueous and ethanolic extracts of *Rhynchosia Beddomei* Baker leaves in Wistar rats**

Ashoka Babu Vechham Lakshminarayana setty<sup>a\*</sup>, Priyanka Agrahari<sup>a</sup>, Ganesan Rajalekshmi Saraswathy<sup>b</sup>,  
Varadarajan Madhavan<sup>a</sup>

<sup>a</sup>Department of Pharmacognosy and <sup>b</sup>Department of Pharmacology, Faculty of Pharmacy, M.S. Ramaiah University of Applied Sciences, Bangalore-54

Received: 30-12-2014 / Revised: 21-01-2015 / Accepted: 25-01-2015

### **ABSTRACT**

The standardized aqueous and ethanol extracts of the dried leaves of *Rhynchosia beddomei* Baker were investigated for their wound healing potential in albino Wistar rats. Incision, excision and dead space wound models were used to evaluate the wound healing property. The leaf extracts were found to possess significant wound healing activity which was evidenced by decrease in the period of epithelization; increase in the rate of wound contraction, skin breaking strength of healed wound, dry weight and tensile strength of granulation tissue. Histopathological study of the granulation tissue confirmed increased collagenation signifying the progress in wound healing. The present study substantiating wound healing effect of the leaf extracts of *Rhynchosia beddomei*.

Keywords: Wound healing activity, *Rhynchosia beddomei* leaves, Incision wound, Excision wound, Dead space wound



### **INTRODUCTION**

*Rhynchosia beddomei* Baker (Papilionaceae) is a rare and endemic medicinal plant found in the Eastern Ghats of Andhra Pradesh [1, 2]. The leaves of the plant are traditionally used for treatment of wounds, cuts, boils and rheumatic pains by the tribal people (Sugali, Yanadi, and Chenchu) dwelling in the forests of Eastern Ghats [2]. The leaves are also known to possess abortifacient, antibacterial, antifungal, antidiabetic and hepatoprotective properties [3, 1].

The phytoconstituents reported in the leaves are flavonoid compounds, alkaloids, glycosides, fatty acids, lignans, triterpenoids and essential oil [2]. The shrub is commonly known as Vendiaku, Vendaku and Vendichettu in Telugu [3]. To our knowledge, there is no wound healing study reported for *Rhynchosia beddomei* Baker. Thus, the present study has been undertaken to ascertain the wound healing activity of the leaves of this species.

### **MATERIAL AND METHODS**

**Plant material:** Leaves of *R. beddomei* were collected from the forests of Tirumala hills, Tirupathi (A.P) during May 2010, authenticated by Dr. K. Madhava Chetty, Taxonomist, SRI Venkateswara University, Tirupathi. A voucher specimen Priyanka agrahari (40) has been deposited at the Department of Pharmacognosy, Faculty of Pharmacy, M.S. Ramaiah University of Applied Sciences, Bangalore.

**Preparation of extracts:** A weighed quantity of the shade dried power of leaves was treated with petroleum ether for de waxing as well as to remove chlorophyll. The powder was dried and extracted with 70% v/v ethanol in a soxhelt apparatus by continuous hot extraction for 72hrs. The alcohol extract was concentrated to a small volume and evaporated to dryness to obtain a dark brown solid extract (15.65 %w/w). The aqueous extraction was obtained by macerating with chloroform-water (0.25 %), for 24hrs. followed by filtration and concentration of the extract to a small volume to obtain a solid dark brown extract (7.5 %w/w). The

extracts were made into a suspension in distilled water and used for further studies.

**Phytochemical Studies:** The extracts were subjected to preliminary phytochemical analysis [4, 5] followed by TLC and HPTLC fingerprinting studies [6, 7]. Camag HPTLC equipped with a linomat V applicator, a TLC scanner 3, reprostar 3, with 12bit CCD camera for photo documentation, controlled by Win CATS- 4 software was used. The mobile phase for both alcohol and aqueous extracts were n-butanol: 27% aq. acetic acid (1:1) [8].

**Animals:** Albino rats of Wistar strain weighing about 170-200 g of either sex were used. The animals were inbred and maintained in the animal house of M. S. Ramaiah College of Pharmacy. Animal house was well maintained under standard hygienic conditions, at a room temperature ( $22 \pm 2^{\circ}$  C) and room humidity ( $60 \pm 10\%$ ) with 12 h day and night cycle, with pellet and water *ad libitum*. The pharmacological experiments were in accordance with CPCSEA guidelines and the studies were approved by Institutional Animal Ethics Committee (No. 220/abc/CPCSEA) of M. S. Ramaiah College of Pharmacy.

**Acute toxicity studies:** The acute toxicity study was carried out as per the OECD - 423 (Organization for Economic co-operation and development) guidelines [9].

### Wound healing activity

**Incision wound model:** Albino Wister rats were randomly divided into four groups of six animals each. Group I was considered as the control, group II served as the reference standard and was treated with topical application of Framycetin sulfate (Soframycin, Aventis) cream. Animals of group III and group IV were treated topically with aqueous extract and alcohol extract (10% w/v) of *Rhynchosia beddomei* respectively. Rats were anaesthetized prior to and during creation of the wound. The dorsal fur of the animal was removed using depilatory cream. A longitudinal paravertebral incision of 6 cm (length) was made through the skin and cutaneous muscle on the back. After the incision, surgical sutures were applied to the parted skin at intervals of 1 cm. The aqueous and alcohol extracts (10% w/v) were topically applied on the undressed wounds once daily, while the standard group was treated with Framycetin sulfate cream and the control animals were left untreated. The sutures were removed on the 8th day post wounding and the treatment was continued. The skin-breaking strength or tensile strength of the healed wound was measured on the 10th day [10] by continuous constant water flow technique [11].

**Excision wound model:** In excision wound model, the animals were divided into four groups of six animals each. The grouping of experimental animals was similar to that of incision wound model. Rats were anaesthetized prior to and during creation of wound. The dorsal fur of the animals was depilated using depilator cream. A round seal of 2.5 cm diameter was impressed on the dorsal thoracic central region 5 cm away from the ears. The entire thickness of the skin from the above marked area was excised out to get a wound measuring around 500mm<sup>2</sup>. The drugs were topically applied daily starting from the day of excision till complete epithelization was observed. The area of the wounds were traced on a graph paper for the area measurement, from the day of creation of wound and subsequently on 2<sup>nd</sup>, 6<sup>th</sup>, 10<sup>th</sup> and 14<sup>th</sup> days post wounding. The parameters studied were the rate of wound closure (contraction of wound) and period of epithelization. The period of epithelization was considered as the number of days for complete healing of wound without any residual wound and scar [12, 13, 14].

**Dead space wound model:** In Dead space wound model the animals were divided into five groups of six animals each. The group I served as control, group II and group III were treated with 200 and 400 mg/kg, p.o. of aqueous extract of *Rhynchosia beddomei* respectively, while the group IV and group V received oral suspension of 200 mg and 400 mg/kg of alcohol extract of *Rhynchosia beddomei* respectively. Wound was created through a small transverse incision made in the lumber region. A pre-weighed (2.5x0.25cm) polypropylene tube was implanted beneath the dorsal paravertebral skin of the anaesthetized rats. The animals were treated orally with extracts from 0 to 9<sup>th</sup> post-implantation day. The granulation tissues formed on the polypropylene tube were harvested on the 10<sup>th</sup> day post-implantation and the breaking strength was measured [11], dried at 60°C overnight and the dry weight of the granulation tissue was determined [12, 14]. A sample of granulation tissue was subjected to histopathological examination to evaluate the effect of the extracts on collagen formation and other related parameters to assess the progress of healing process.

**Statistical analysis:** The data were subjected to ANOVA followed by Tukey's Kramer multiple comparison tests and the values of P < 0.05 were considered statistically significant.

## RESULTS

Preliminary phytochemical screening revealed the presence of carbohydrates, phytosterols, tannins,

flavonoids, volatile oil, gums and mucilage. HPTLC fingerprint studies for the presence of flavonoids in alcohol extract revealed the presence 9 peaks ( $R_f$  0.02, 0.10, 0.35, 0.42, 0.55, 0.68, 0.76, 0.86, 0.91) at 366nm (fig 1a). Aqueous extracts gave 8 peaks ( $R_f$  0.10, 0.34, 0.36, 0.53, 0.72, 0.82, 0.91, and 0.96) at 366nm (fig 1b).

Acute toxicity studies of aqueous and alcohol extracts 300 and 2000 mg/kg were carried out on Wister albino rats of either sex. The extracts were found to be non lethal up to 2000 mg/kg.

In incision wound model, significant increase in wound breaking strength was observed with both aqueous ( $P < 0.05$ ) and alcohol ( $P < 0.01$ ) extract treated groups when compared with the control group (Table 1).

In excision wound model, the rate of wound contraction and period of epithelization were observed in excision wound model. The wound area was measured at fixed time intervals, from the day of creation of wound 2<sup>nd</sup>, 6<sup>th</sup>, 10<sup>th</sup> and 14<sup>th</sup> days after induction of the wound. The percentage wound contraction was found to be 87.4, 81.72 and 83.475 for soframycin, aqueous and alcohol extracts treated groups respectively on 14<sup>th</sup> post wounding day when compared with the control group. Both the extracts exhibited a significant wound contraction on the 14<sup>th</sup> day when compared with the control group.

Period of epithelization was found to be 20, 21 and 23 days for the standard, alcohol and aqueous extracts respectively, whereas the epithelization period was 24 days for the control group animals. Both alcohol ( $P < 0.001$ ) and aqueous ( $P < 0.01$ ) extracts exhibited a significant contraction in area of the wound. This decrease in epithelization period indicates the wound healing effect of the drug (Table 2).

In dead space wound model dry weight and breaking strength of granulation tissue were studied on 10<sup>th</sup> post wounding day. A significant increase in breaking strength was observed with 200mg/kg ( $P < 0.01$ ), 400mg/kg ( $P < 0.001$ ) of alcohol extract and 200mg/kg ( $P < 0.05$ ), 400mg/kg ( $P < 0.01$ ) of aqueous extract, when compared with control group. The treatment groups showed an increase in mean dry weight of granulation tissue. Aqueous and alcohol extract at 400mg/kg exhibited an extremely significant ( $P < 0.001$ ) increase in dry weight of granulation tissue, whereas 200mg/kg of aqueous ( $P < 0.05$ ) and alcohol ( $P < 0.01$ ) extract significant in dry weight of granulation tissue as compared to the control (Table 3).

**Histopathology:** The granulation tissues harvested from dead space wound model on 10<sup>th</sup> day were subjected to histopathological analysis. Normal group showed undisturbed architecture. Control group (untreated) showed no collagen formation with predominantly inflammatory cells, few macrophages and capillaries indicating the persistence of wound. Aqueous extract at the dose of 200 mg/kg displayed scant collagen formation with many fibroblasts and moderate number of macrophages and capillaries, whereas aqueous extract at the dose of 400 mg/kg and alcohol extract at the dose of 200 mg/kg demonstrated collagen formation with focal fibres and fibroblasts and mild to moderate number of macrophages and capillaries, signifying the progress in wound healing. Alcohol extract of 400 mg/kg exhibited predominant collagen formation with thick bundles and few fibroblasts, and scanty or no macrophages and capillaries, evidencing the improvement in the wound healing process.

## DISCUSSION

Wound healing is a process involving restoration of tissue integrity due to the formation of the connective tissue matrix. The process of wound healing comprises different phases such as contraction, epithelization, granulation and collagenation. Collagen is a major protein of extracellular matrix and is the component that ultimately contributes to tensile strength of closed wound [15]. Hence, three different models have been chosen in this study to assess the effect of *R. beddomei* Baker (leaves) on wound healing.

The wound breaking strength is determined by the rate of collagen synthesis and by the maturation process where there is covalent binding of collagen fibrils through an inter and intra molecular cross linking [12, 16]. In incision wound model, a significant increase in wound breaking strength was observed with alcohol and aqueous extract treated groups on 10<sup>th</sup> day when compared with the control group. This shows an increased the rate of collagen synthesis and maturation process which improving the quality of collagen fibrils.

Wound contraction is the process of inward mobilization of healthy skin surrounding the wound to cover the wounded area. This centripetal movement of wound margin promotes epithelization either by facilitating the proliferation of epithelial cell or by increasing the viability of epithelial cells [12, 17]. In excision wounds, both the extracts of *R. beddomei* Baker exhibited significant effect in wound contraction and complete epithelization period by the 14<sup>th</sup> post wounding, when compared with the control group.

Hence, it appears that *R. beddomei* showed significant increased in wound contraction and promote epithelization.

Increase in breaking strength of granulation tissue indicates increased cross linking followed by enhanced collagen maturation whereas dry weight of granulation tissue indicates the presence of higher protein content, which in turn is related to healing property [15]. In dead space wound model, both the extracts at a higher dose exhibited a significant increase in dry weight of granulation tissue and breaking strength of the same. Histopathological examination revealed predominant collagen formation, increased capillaries, few fibroblasts and scant or no macrophages in animals treated with 400 mg/kg evidencing the improvement in wound healing. Phytoconstituents like flavonoids and tannin are reported to be responsible for wound healing property in the plants [18, 19, 13]. In the present investigation, preliminary phytochemical analysis

of the extracts of *R. beddomei* showed the presence of carbohydrates, phytosterols, phenolic compounds, tannins, flavonoids, volatile oil, gums and mucilage. Drugs that inhibit lipid peroxidation are believed to increase the viability of collagen fibrils by increasing their strength, improving the circulation, preventing the cell damage and promote the DNA synthesis [20]. Flavonoids are known to reduce lipid peroxidation not only by preventing or slowing the onset of cellular necrosis but also by improving vascularity [19]. Flavonoids and tannins reported to be responsible for wound healing activity [21]. The presence of these constituents in the leaves of *R. beddomei* Baker may be responsible for the wound healing activity.

**ACKNOWLEDGEMENTS**

The authors are thankful the Management of Gokula Education Foundation for providing all facilities, encouragement and financial support throughout this work.

**Table.1 Effect of *R. beddomei* leaves extracts on breaking strength of incision wound model**

Treatment	Day 2 <sup>nd</sup> %contraction	Day 6 <sup>th</sup> %contraction	Day 10 <sup>th</sup> %contraction	Day 14 <sup>th</sup> %contraction	Period of epithelization
Control	12.83 ± 0.88	36.09 ± 1.538	52.2916 ± 1.763	76.478 ± 0.8947	24.5 ± 0.2236
Standard group (Soframycin)	26.39 ± 3.612**	43.83 ± 0.8563***	71.2033 ± 1.415***	87.4 ± 1.364***	20.33 ± 0.210***
Aqueous extract ( <i>R. beddomei</i> )	22.44 ± 2.451*	40.6235 ± 0.9068*	62.968 ± 1.980**	81.72 ± 0.5156**	23.0 ± 0.3651**
Alcohol extract ( <i>R. beddomei</i> )	24.335 ± 1.759*	41.553 ± 0.798**	67.975 ± 1.482***	83.475 ± 0.3340***	21.5 ± 0.342***

n = 6 animals in each group. Values expressed as Mean ± SEM

\* P < 0.05, \*\* P < 0.01, \*\*\* P < 0.001, as compared with control

**Table 2:- Effect of *R. beddomei* leaves extracts on excision wound model**

	Control	Standard (Soframycin)	Aqueous extract ( <i>R. beddomei</i> )	Alcohol extract ( <i>R. beddomei</i> )
Breaking strength (g)	758.3 ± 67.6	1575 ± 148.2***	1116.6 ± 24.72*	1225 ± 44.1**
p value	—	<0.001	<0.05	<0.01

n = 6 animals in each group. Values expressed as Mean ± SEM

\* P < 0.05, \*\* P < 0.01, \*\*\* P < 0.001, as compared with control

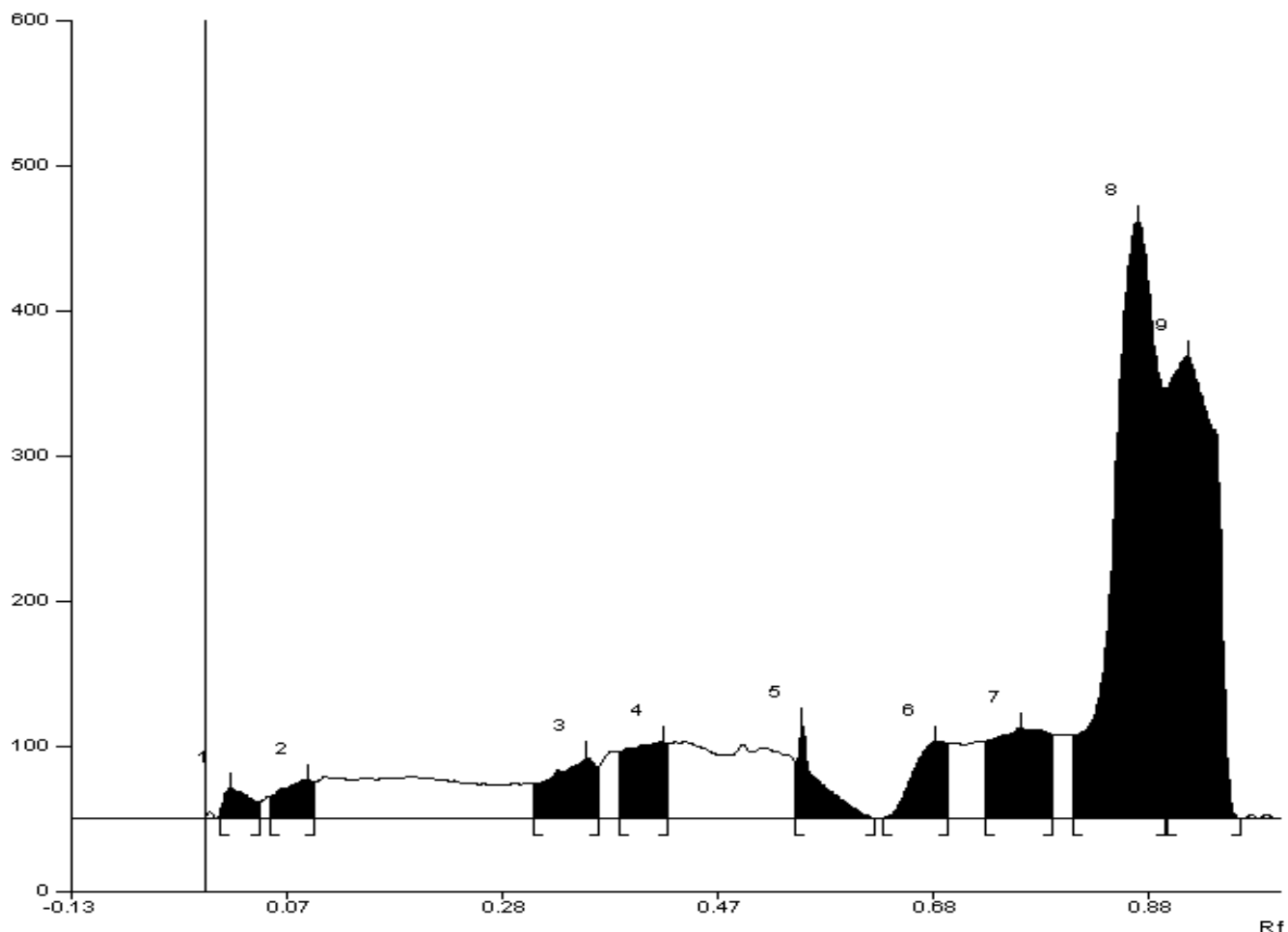
**Table 3:- Effect of *R. beddomei* leaves extracts on dead space of wound healing activity**

Sl.No	Groups	Dry Weight(mg)	Breaking Strength (g)
1	Untreated control	34.836 ± 1.302	237.5 ± 3.936
2	Aqueous extract (200mg/kg)	56.081 ± 2.514*	341.666 ± 23.86*
3	Alcohol extract(200mg/kg)	60.078 ± 2.897**	366.66 ± 21.082**
4	Alcohol extract (400mg/kg)	90.896 ± 6.872***	458.33 ± 23.86***

n = 6 animals in each group. Values expressed as Mean ± SEM

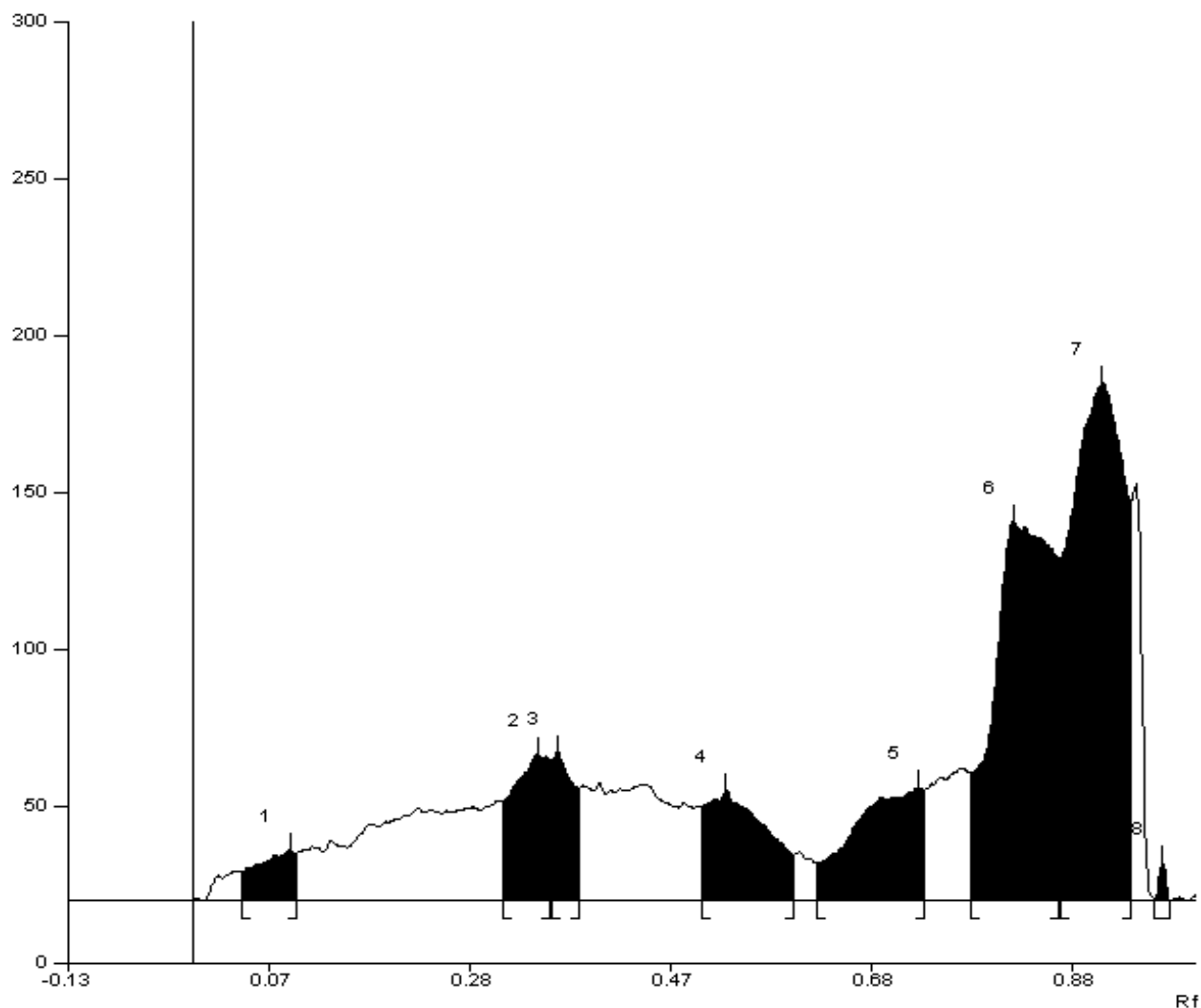
\* P < 0.05, \*\* P < 0.01, \*\*\* P < 0.001, as compared with control

**Fig.1.a: HPTLC fingerprint of alcohol extract for flavonoids of *R. beddomei* at 366nm**



Peak	Start Position	Start Height	Max Position	Max Height	Max %	End Position	End Height	Area	Area %
1	0.05 Rf	9.3 AU	0.10 Rf	16.2 AU	3.37 %	0.10 Rf	15.0 AU	576.2AU	2.60%
2	0.31 Rf	31.8 AU	0.34 Rf	46.6 AU	9.72%	0.35 Rf	44.7 AU	1577.9 AU	7.11 %
3	0.36 Rf	44.4 AU	0.36 Rf	47.3 AU	9.86 %	0.38 Rf	35.9 AU	956.7AU	4.31 %
4	0.51 Rf	30.0 AU	0.53 Rf	35.1 AU	7.33 %	0.60 Rf	14.6 AU	1959.0 AU	8.83 %
5	0.62 Rf	12.1 AU	0.72 Rf	36.1 AU	7.54 %	0.73 Rf	35.3AU	2258.5 AU	10.17 %
6	0.78 Rf	40.6 AU	0.82 Rf	120.9 AU	25.22%	0.86 Rf	38.9 AU	6668.4 AU	30.04%
7	0.86 Rf	109.3AU	0.91 Rf	164.8 AU	34.38 %	0.93 Rf	27.1AU	8127.4 AU	36.61%
8	0.96 Rf	0.5 AU	0.96 Rf	12.3 AU	2.58 %	0.97 Rf	0.0AU	73.8 AU	0.33%

**Fig. 1.b: HPTLC fingerprint of aqueous extract for flavonoids of *R. beddomei* 366nm**



Peak	Start Position	Start Height	Max Position	Max Height	Max %	End Position	End Height	Area	Area %
1	0.05 Rf	9.3 AU	0.10 Rf	16.2 AU	3.37 %	0.10 Rf	15.0 AU	576.2AU	2.60%
2	0.31 Rf	31.8 AU	0.34 Rf	46.6 AU	9.72%	0.35 Rf	44.7 AU	1577.9 AU	7.11 %
3	0.36 Rf	44.4 AU	0.36 Rf	47.3 AU	9.86 %	0.38 Rf	35.9 AU	956.7AU	4.31 %
4	0.51 Rf	30.0 AU	0.53 Rf	35.1 AU	7.33 %	0.60 Rf	14.6 AU	1959.0 AU	8.83 %
5	0.62 Rf	12.1 AU	0.72 Rf	36.1 AU	7.54 %	0.73 Rf	35.3AU	2258.5 AU	10.17 %
6	0.78 Rf	40.6 AU	0.82 Rf	120.9 AU	25.22%	0.86 Rf	38.9 AU	6668.4 AU	30.04%
7	0.86 Rf	109.3AU	0.91 Rf	164.8 AU	34.38 %	0.93 Rf	27.1AU	8127.4 AU	36.61%
8	0.96 Rf	0.5 AU	0.96 Rf	12.3 AU	2.58 %	0.97 Rf	0.0AU	73.8 AU	0.33%

## REFERENCES

1. Bakshu L Md, Raju RRV. Chemical characterization of Essential oil of *Rhynchosia beddomei*. Journal of Applied Biological Sciences 2009; 3(1): 31-32.
2. Bakshu L Md, Raju RRV. Antimicrobial activity of *Rhynchosia beddomei*. Fitoterapia 2001; 72: 579-82.
3. Chetty KM et al. *Flowering plants of Chittoor district Andhra Pradesh India*, 1st ed; Student offset printers: Tirupati, 2008.
4. Harborne JB. *Phytochemical methods*, 3<sup>rd</sup> ed; Chapman and Hall: London, 1998.
5. Raaman N. *Phytochemical Technique*, 1st ed; New India publishing agency: New Delhi, 2006.
6. Stahl E. *Thin layer chromatography. A Laboratory Hand Book*, 2<sup>nd</sup> ed; Springer: Berlin, 2005.
7. Wagner H, Bladt S. *Plant Drug Analysis*, 2nd ed; Springer: Berlin, 1996.
8. Nair AGR, Ramesh P, Subramanian SS. Occurrence of glycoflavones in the Acanthaceae. Photochemistry 1975; 14: 1644.
9. OECD/OCDE, OECD guidelines for testing of Chemical-423 2001.
10. Nayak BS, Pereira LMP. *Catharanthus roseus* flower extract has wound healing activity in Sprague dawley rats. BMC Altern med 2006; 6: 41.
11. Lee KH. Studies on the mechanism of action of salicylate II. Retardation of wound healing by aspirin. J Pharmacol Sci 1968; 1042-3.
12. Shanbhag TV et al. Wound healing activity of alcoholic extract of *Kaempferia Galanga* in Wistar rats. Indian J Physiol pharmacology 2006; 50(4): 384-90.
13. Madhavan V et al. Wound healing and antipyretic activity of stem bark of *Wrightia tinctoria*. J Trop Med Plants 2006; 7(1): 69-73.
14. Bigoniya P, Rana AC. Wound healing activity of *Euphorbia nerifolia* leaf ethanolic extracts in rats. Journal of Natural Remedies 2007; 7(1): 94-101.
15. Manjunatha BK et al. Wound healing potency of *Mucuna monosperma*. J. Trop. Med. Plants 2005; 6(1): 7-13.
16. Shirweiker A et al. Wound healing property of leaves of *Hyptis suaveojeans* with supportive role of antioxidant enzymes. Indian J Exp Biol. 2003; 41: 238-41.
17. Gabbaiani G, Harschel BJ, Ryan GB. Granulation tissue as a contractile organ. J Exp Med. 1976; 135: 719.
18. Kiran K, Asad M. Wound healing activity of *Sesamum indicum* L seed and oil in rats. Indian journal of experimental biology 2008; 46: 777-82.
19. Manjunatha BK, Vidya SM, Rashmi KV. Evaluation of wound healing potency of *Vernonia arborea* HK. Indian Journal of Pharmacology 2005; 4(37):223-26.
20. Getie M et al. Evaluation of the release profiles of flavonoids from topical formulations of the crude extract of the leaves of *Dodonea viscosa* (Sapindaceae). Pharmazie 2002; 57: 320-22.
21. Ya C et al. Carbohydrate- polyphenol complexation In: *Hemingway RW, Karchesy JJ, eds. Chemistry and significance of condensed tannins*, 1st ed, Plenum press: New York, 1988; 132.