



WOUND HEALING POTENTIAL OF LEAVES OF *EUCALYPTUS CITRIODORA* IN RATS

C. Velmurugan*¹, C. Geetha¹, SK. Shajahan¹, S. Vijayakumar² and P.R. Logesh Kumar³

¹Department of Pharmacology, ²Department of Pharmacognosy and ³Department of Pharmaceutical Chemistry, Sri Krishna Chaithanya College of Pharmacy, Gangannagaripalle, Madanapalle, Andhra Pradesh-517325, India

Received: 17-10-2013 / Revised: 23-10-2013 / Accepted: 15-12-2013

ABSTRACT

The aim of the study was to evaluate the effects of *Eucalyptus citriodora* (EAEEC) ethyl acetate and ethanol (EEEC) extracts on wound healing activity. Excision, incision and dead space wound healing activity was examined on wistar rats, dressed with 10% and 200 mg/kg p.o of the extracts respectively. Control groups were dressed with the simple ointment (negative control) and 5% povidone-iodine (standard) respectively. Healing was assessed based on contraction of wound size, mean epithelisation time, hydroxyproline content and histopathological examinations. Excision wound healing study revealed significant reduction in wound size and mean epithelisation time and scar area. In incision model showed significant ($p < 0.01$) variation in breaking strength and dead space model shows increase wet & dry weight of cotton pellet this indicate higher collagen synthesis in the 10% extract-treated group compared to the vehicle group. These findings were supported by histopathological examinations of healed wound sections which showed greater tissue regeneration, more fibroblasts and angiogenesis in the 200 mg/kg extract-treated group. The extracts of *Eucalyptus citriodora* is a potential candidate for the treatment of dermal wounds by topical and oral administration. The extracts are deduced to have accelerated the wound repair at all the phases of the healing.

Key words: *Eucalyptus citriodora*, wound, hydroxyproline, Excision, incision and dead space model

INTRODUCTION

The World Health Organization estimated that 80% of people worldwide rely on herbal medicines for some aspect of their primary healthcare [1]. The aim of herbal treatment is usually to produce persisting improvements in wellbeing. Practitioners often talk in terms of trying to treat the “underlying cause” of disease and may prescribe herbs aimed at correcting patterns of dysfunction rather than targeting the presenting symptoms [2].

Wound infection is one of the most common diseases in developing countries because of poor hygienic conditions [3]. Wounds are the physical injuries that result in an opening or breaking of the skin and appropriate method for healing of wounds is essential for the restoration of disrupted anatomical continuity and disturbed functional status of the skin [4]. In other words wound is a

break in the epithelial integrity of the skin and may be accompanied by disruption of the structure and function of underlying normal tissue and may also result from a contusion, haematoma, laceration or an abrasion [5]. Research on wound healing agents is one of the developing areas in modern biomedical sciences and many traditional practitioners across the world particularly in countries like India and China have valuable information of many lesser-known hitherto unknown wild plants for treating wounds and burns [6]. Traditional forms of medicine practiced for centuries in Africa and Asia are being scientifically investigated for their potential in the treatment of wounds related disorders [7]. *Eucalyptus citriodora* L of the family Myrtaceae is commonly known as Eucalyptus [Batish DR]. The medicinal properties of Eucalyptus and other parts of the plants are well known in traditional system of medicine all species of eucalyptus leaves have been used in traditional

*Corresponding Author Address: C. Velmurugan, Assistant Professor, Department of Pharmacology, Sri Krishna Chaithanya College of Pharmacy, Gangannagaripalle, Madanapalle, Andhra Pradesh-517325, India; E-mail: velu0906@gmail.com

Aboriginal bush medicine for thousands of years. Infusions made of *E. citriodora* leaves were taken internally to reduce fevers and ease gastric conditions, and applied externally as a wash for the analgesic, anti-fungal and anti-inflammatory properties. Aborigines would make leaves into a poultice and apply them to ease joint pain and speed up the healing of cuts, skin conditions, wounds and infections. Respiratory infections, colds and sinus congestion were treated by inhaling the vapours of steamed leaves, and to treat rheumatism the leaves were made into beds or used in steam pits heated by fire. The therapeutic qualities of the leaves and its essential oil were eventually introduced and integrated into many traditional medicine systems, including Chinese, Indian Ayurvedic and Greco-European. The essential oil found in the leaves is a powerful antiseptic. The essential oil obtained from the leaves is antibacterial. The oil can be gargled for sore throat and can also take internally for a wide range of complaints. The resin contains tannin and is powerful astringent. It is used internally in the treatment of diarrhea and bladder inflammation. A lemon-scented essential oil is obtained from the leaves. It is used especially in perfumery but also medicinally. The leaves and resin used as antiproliferative [8]. In the traditional system of medicine, the leaves are reported to be useful in the treatment of wound healing [9]. However, there are no records of systematic pharmacological studies that support the claim of traditional use of *Eucalyptus citriodora* leaves for treatment of wound healing. The present study, an effort has been made to establish the scientific validity for the wound healing property of ethyl acetate and ethanolic extracts of *Eucalyptus citriodora* leaves using rats.

MATERIAL AND METHODS

Collection and authentication of the plant material: The leaves of *Eucalyptus citriodora* had been collected from the field of Government hospital, Madanapalle, Chittoor District, Andhra Pradesh, India. The plant was identified and authenticated by the Botanist Dr. K. MadhavaChetty, Assistant Professor, Department of botany, Sri Venkateswara University, Tirupathi.

Extraction and phytochemical analysis: The fresh leaves of *Eucalyptus citriodora* were collected and dried under shade and ground into powder with mechanical grinder. The powder was passed through sieve no.30 and stored in a container. The dried powder of leaves of *Eucalyptus citriodora* was defatted with petroleum ether. The defatted powder material (marc) thus obtained was successively extracted with Ethyl acetate and

ethanol by maceration. The solvent was removed by distillation under reduced pressure and evaporation. The resulting semisolid mass was vacuum dried by using rotary flash evaporator. Final extract was screened for the presence of various phytoconstituents like alkaloids, flavonoids, saponin, tannin, carbohydrates and glycosides etc. [10]

Experimental Animals: All the experiments were carried out using Wistar albino rats (150-200 g). The animals were placed at random and allocated to treatment groups in polypropylene cages with paddy husk as bedding. Animals were housed at a temperature of $24 \pm 2^\circ\text{C}$ and relative humidity of 30–70%. A 12:12 light: day cycle was followed. All animals were allowed free access to water and fed. Ethical clearance was obtained from Institutional Animal Ethical Committee (IAEC) of Sri Krishna Chaithanya College of pharmacy, Madanapalle, Andhra Pradesh. No: SKCP/IAEC/PGCOL/11-12/08.

Acute toxicity studies [11]:

The acute toxicity study was carried out with extracts of EC as per OECD 423 Guidelines. Wistar albino mice with weight ranging (25-30 g) were taken for the experiment. The animals were made into a group of 3 each, dose of ethyl acetate and ethanol extracts were given according to the body weight (mg/kg), starting dose of 5 mg/kg was given to the first individual animal, no death was occurred, higher doses were given to next group of animals. The animals were observed for a further 14 days for any signs for delayed toxicity.

Number of animals	Dose in mg/kg	Report
3	5mg/kg	No death
3	50mg/kg	No death
3	500mg/kg	No death
3	2000mg/kg	No death

From the observation the ethyl acetate and ethanol extracts of leaves of *Eucalyptus citriodora* were screened for acute toxicity study by OECD guidelines 423 for determining the LD₅₀. The results showed that LD₅₀ was found to be 2000mg/kg. Therefore studies carried out with 1/10th of LD₅₀ as 200mg/kg.

Formulation of crude extracts: The concentrations of the both extracts ointment was formulated using simple ointment base as the

vehicle. For 10% (w/w) extracts ointment, 10 g of the dry ethyl acetate extract was incorporated in 100 g of ointment base and warmed at 50-55°C, with constant stirring until a homogeneous extract-cream formation was obtained. For 10% (w/w) ethanol ointment, 10 g of the dry ethanol extract was used in place of 10 g of the ethyl acetate extract. The extract ointment was weighed into eppendorff tubes and left to equilibrate at room temperature for 3 days, before use.

Wound healing activity in rats:

Excision wound

Wistar albino rats weighed about 150-200g were divided into four groups of six rats each.

Group I : Negative control simple ointment applied topically.

Group II: 5% w/w Povidone iodine ointment applied topically.

Group III : 10% EAEEC in ointment applied topically

Group IV : 10% EEEEC in ointment applied topically

All animals were anesthetized prior to and during creation of the wounds with ketamine hydrochloride (ip, 100 mg/kg). The rats were inflicted with excision wounds as described by Morton and Malone [12] and suggested by Kamath *et al.*[13]. An impression was made on the dorsal thoracic region 1 cm away from vertebral column and 5 cm away from ear on the anesthetized rat. The dorsal fur of the animals was shaved with an electric clipper and the anticipated area of the wound to be created was outlined on the back of the animals with methylene blue using a circular stainless steel stencil. A full thickness of the excision wound of circular area of 500 mm² and 2 mm depth was created along the markings using toothed forceps, scalpel and pointed scissors. Haemostasis was achieved by blotting the wound with cotton swab soaked in normal saline. The entire wound was left open [14]. All surgical procedures were performed under aseptic conditions. Animals were treated daily with drugs from 0th day to 11th post-wounding day. The wound closure rate was assessed by tracing the wound using transparent paper and a permanent marker. The wound areas recorded were measured using graph paper [15, 16]. The percentage of wound size for each animal of group on predetermined days i.e. 0, 3, 6, 9 and 11 post –wounding days for final analysis of results. Changes in wound area were calculated, giving an indication of the rate of wound contraction. The period of epithelialisation was calculated as the number of days required for

falling of the dead tissue remnants without residual raw wound.

Incision wound

Wistar albino rats weighed about 150-200g were divided into four groups of six rats each.

Group I : Control simple ointment applied topically.

Group II: 5% w/w Povidone iodine ointment applied topically.

Group III : 10% EAEEC ointment applied topically.

Group IV : 10% EEEEC ointment applied topically.

The rats were anaesthetized prior to and during creation of the wounds with ketamine hydrochloride (ip, 100 mg/kg). The dorsal fur of the animals was shaved with an electric clipper. A longitudinal paravertebral incision of 5 cm long was made through the skin and cutaneous tissue on the back as described by Ehrlich and Hunt [17]. After the incision, the parted skin was sutured 1 cm apart using a surgical thread and curved needle. The wounds were left undressed [18]. The sutures were removed on 8th post wound day and continued the application of the extract. Animals were treated daily with drugs as mentioned above from 0th day to 10th post-wounding day. The wound breaking strength [19] was determined on 10th day by tensiometer.

Dead space wound model

Wistar albino rats weighed about 150-200g were divided into three groups of six rats each.

Group I : Negative control.

Group III : received 200 mg/kg EAEEC orally.

Group IV : received 200 mg/kg EEEEC orally.

Dead space wounds were inflicted by implanting sterile cotton pellets (10 mg each), one on either side in the groin region on the ventral surface of each rat. All animals treated daily as mentioned above in this model from 0th day to 10th post wounding day. On the 10th post wounding day, the granulation tissue formed on the implanted cotton pellets was carefully removed under anesthesia. The wet weight of the granulation tissue collected was noted. The tissue samples were dried at 60° C for 12 h and weight was recorded [20].

Determination of total collagen - Hydroxyproline assay [21]:

On the 10th day, the animals from each group were euthanized using diethyl ether and used to determine hydroxyproline content. The protein content of the tissue was estimated using the techniques described by Neuman and Logan¹⁷. The granulation tissue was

hydrolyzed in 6N HCl for 24 h at 110°C in sealed glass tubes. The hydrolysate was neutralized to pH 7.0. The samples (200µl) were mixed with 1ml of 0.01M CuSO₄ followed by the addition of 1ml of 2.5N NaOH and then 1ml of 6% H₂O₂. The solution was mixed and shaken occasionally for 5 min. All the tubes were incubated at 80 °C for 5min with frequent vigorous shaking. Upon cooling, 4ml of 3N H₂SO₄ was added with agitation. Finally, 2ml of 5% p-dimethylaminobenzaldehyde was added. The samples were incubated at 70 °C for 16 min, cooled by placing the tubes in water at 20 °C, and the absorbance was measured at 500 nm using a digital photo colorimeter (EI Products, India). The amount of Hydroxyproline in the samples was calculated using a standard curve prepared with pure L-Hydroxyproline at the same time.

Histopathological studies: For histological studies, pieces of granulation tissues from dead space wound model were fixed in 10% neutral formalin solution for 24 h and dehydrated with a sequence of ethanol-xylene series of solutions. The materials were filtered and embedded with paraffin (40-60 °C) and 3 µm microtome sections were taken. The sections were processed in alcohol-xylene series and stained with hemotoxylin-eosin dye. The histological changes were observed under a microscope. Slides were examined qualitatively under a light microscope, for collagen formation, fibroblast proliferation, angiogenesis, epithelization and granulation tissue formation [22].

Statistical analysis: Experimental data are expressed as mean±standard error of mean (SEM). Statistical analysis was performed by one-way ANOVA followed by Dunnett's method of multiple comparisons was employed using GraphpadInstat 3.0 software. Data were considered significant at p< 0.01 & p< 0.05.

RESULTS

Preliminary phytochemical screening: The preliminary phytochemical analysis of extracts of *Eucalyptus citriodora* shows presence of flavonoids, glycosides, tannin, alkaloids, phenolic compound and carbohydrate.

Excision wound: In an excision wound model the extracts EAEPC and EEPC at a dose of 200mg/kg showed significant (p<0.01) wound healing activity on 11th day by increased wound contraction and % of wound contraction (62.8±11.46, 68.03±14.98)(87.4 & 86.3) compare to control (177.9±22.44) (64.4%) and no significant to standard (52.3±10.46) (89.5%). The extracts and standard showed significant changes in complete

epithelization (13.16±0.75, 13.83±0.75 & 12.94±0.51 days) when compared to control (16.25±1.16 days). It's also showed a scar area of 16.23±2.55, 16.96±3.23 & 15.54±2mm² as compared to control 21.61±2.92mm².

Incision and Cotton pellet granuloma models: In incision and cotton pellet granuloma models, the extracts and standard showed significant different in tensile strength 355.83±8.88, 392.16±9.75 & 459.5±8.10 when compared to control (180.33±9.21) and also showed significant increase in wet and dry weight [(178.83±3.22 169.16±4.38 & 186.5±2.04) (49.5±1.50, 46.83±1.8 & 51.66±1.44)] of cotton pellet compared to control [(118.83±3.25) (34.66±1.56)] in cotton pellet model. Increase in hydroxyproline content indicates increased collagen synthesis which in turn leads to enhanced wound healing. The hydroxyproline content was found to be significantly increased in Group-II, III & IV (p < 0.01) as compared with control.

DISCUSSION

Wound healing involves various phases. Initially involves acute inflammatory phase followed by the synthesis of collagen and other extra cellular macromolecules, which are later removed to form a scar [23]. Drugs, which influence one phase, may not necessarily influence another. Hence different models have been used in our study to assess the effect of various phases. The present studies reflected that ethyl acetate and ethanol extracts of leaves of *Eucalyptus citriodora* (200 mg/kg) was effective in all the models of wound healing activity. The study of the effect on excision model showed that the *Eucalyptus citriodora* increased the wound contraction, decreased epithelization and scar area. The treated group of wound showed complete healing of wounds with almost normal architecture of the collagen and reticulin. Significant increase in skin breaking strength which was a reflection of increased collagen levels by increased cross linking of collagen fibers. In addition, increase in dry granulation tissue weight indicated the presence of higher protein content [24]. The above statement was proved by results of hydroxyproline estimation. Earlier studies revealed Flavonoids have therapeutic uses due to their antiinflammatory, antifungal, antioxidant and wound healing properties [25-28]. Moreover, flavonoids and their derivatives are known to decrease lipid peroxidation by improving vascularity and preventing or slowing down the progress of cell necrosis. Flavonoids are also known to endorse wound healing processes primarily owing to their antimicrobial and

astriquent properties, which appear to be responsible for wound contraction and elevated rate of epithelization [29].

In other study, Polyphenolic flavonoids and tannins are reported to facilitate wound healing [30]. Once again the earlier report confirmed that Proanthocyanidins or condensed tannins are a group of biologically active polyphenolic bioflavonoids that are synthesized by many plants. Proanthocyanidins and other tannins are known to facilitate wound healing [31, 32]. Tannins promote wound healing through several cellular mechanisms: scavenging of free radicals and reactive oxygen species, promoting contraction of the wound and increasing the formation of capillary vessels and fibroblasts [33]. The present study, phytochemical screening confirmed that extracts of *EC* contains flavonoids, tannins, alkaloids and phenolic compounds. The wound healing potential of the extracts of *EC* could be due to the interaction

of the mixture of these phyto-constituents with various phases of wound healing.

CONCLUSION

The results revealed a potential for extracts of *Eucalyptus citriodorato* be used as an external and internal application for the treatment of wounds. The extracts ointment 10% (w/w) concentration was capable of producing significant wound healing activity. Histopathological findings correlated well with wound contractions, mean epithelisation time study and the biochemical marker test of hydroxyproline. The mechanism of action of the extracts was postulated to be via angiogenesis, collagen deposition, granulation tissue formation, epithelization and wound contraction at the proliferative stage and these actions are attributed to the synergistic effects of the phytoconstituent like phenolic compound, flavanoids and tannins in the extract.

Table 1: Preliminary phytochemical screening of the ethyl acetate and ethanolic extract of leaves of *Eucalyptus citriodorato*

Extracts	Steroids	Alkaloids	Glycosides	Saponin	Flavonoid	Tannin	Phenolic compound	carbohydrate
Ethyl acetate	+	+	+	-	+	+	+	+
Ethanol	+	+	+	-	+	+	+	+

Where + =present, - =absent

Table 2: The effect of *Eucalyptus citriodorato* on wound area in excision wound model in normal rats

Groups	Treatment	Excision wound				
		Wound area in mm ²				
		0 th day	3 th day	6 th day	9 th day	11 th day
I	Simple ointment	500	450.6±33.09	392.5±36.03	256.4±35.72	177.9±22.44
II	Povidone ointment	500	306.65±23.61**	260.7±15.29*	132.45±10.92**	52.3±10.46**
III	EAEEC	500	303.01±20.57**	249.3±48.0*	141.3±23.98**	62.8±11.46**
IV	EEEEC	500	328.98±21.66**	254.5±22.78*	146.5±20.93*	68.03±14.98**

Values are expressed as Mean±SEM. Significant (*p< 0.05 & **p <0.01) compared with treated groups Vs control.

Table 3: Percentage of wound contraction

Groups	Treatment	Excision wound				
		% of wound contraction				
		0 th day	3 th day	6 th day	9 th day	11 th day
I	Simple ointment	500	9.88%	21.5%	48.7%	64.4%
II	Povidone ointment	500	38.6%	47.8%	73.5%	89.5%
III	EAEEC	500	39.3%	50.14%	71.7%	87.4%
IV	EEEEC	500	34.2%	49.1%	70.7%	86.3%

Table 4: The effect of *Eucalyptus citriodorato* on excision wound model in normal rats

Groups	Treatment	Mean size of scar area in mm ²	Period of epithelization (days)
I	Simple ointment	21.61±2.92	16.25±1.16
II	Povidone ointment	15.54±2**	12.94±0.51**
III	EAEEC	16.23±2.55**	13.63±0.75**
IV	EEEEC	16.96±3.23**	13.83±0.75**

Values are expressed as Mean±SEM. Significant (**P <0.01) compared with treated groups Vs control.

Table 5: the effect of extracts of *Eucalyptus citriodora* on incision wound

Groups	Treatment	Tensile strength in gm
I	Simple ointment	231.6±21.66
II	Povidone ointment	464.16±33.32**
III	EAAEEC	436.6±70.12**
IV	EEEC	420±60.93**

Values are expressed as Mean±SEM. Significant (**p<0.01) compared with treated groups Vs control.

Table 6: The effect of extracts of *Eucalyptus citriodora* on dead space model

Groups	Treatment	Wet weight in gm	Dry weight in gm	Hydroxyproline in µg
I	Control	121.6±11.66	45.5±3.75	1159.33±2.39
II	EAAEEC	195±14.77**	89.16±11.86**	1983.66±3*
III	EEEC	180.8±10.19**	85.5±6.85**	1761.5±2.96*

Values are expressed as Mean±SEM. Significant (*p <0.05 & **p<0.01) compared with treated groups Vs control.

Histopathological study of granulation tissue

Group I animal (control) showing with less collagen and more macrophages. Histology of granulation tissue of group II & III (ethyl acetate extract & ethanol extract) animal showing more collagen, fibroblasts, and blood capillaries with less macrophages.

Figure 1: Control

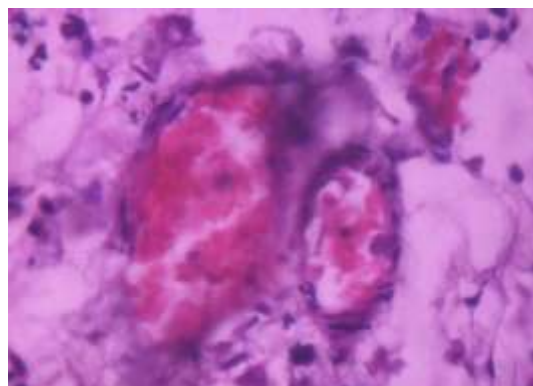


Figure 1: EAAEEC 200 mg/kg

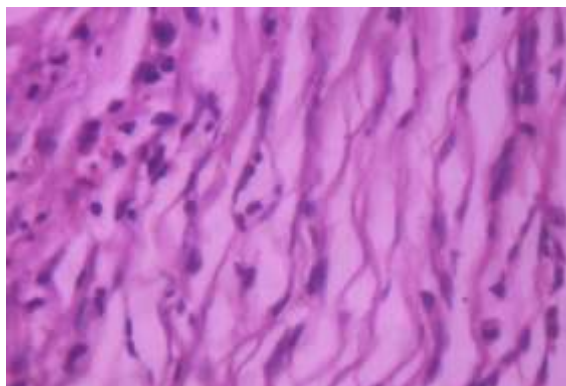
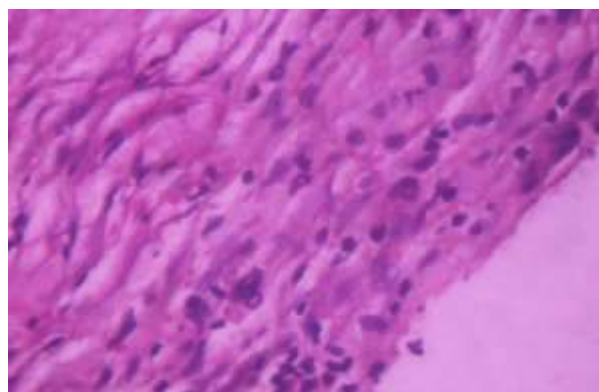


Figure 1: EEEEC 200 mg/kg



Effect of extracts of excision wound

Figure 1: Control 0th day

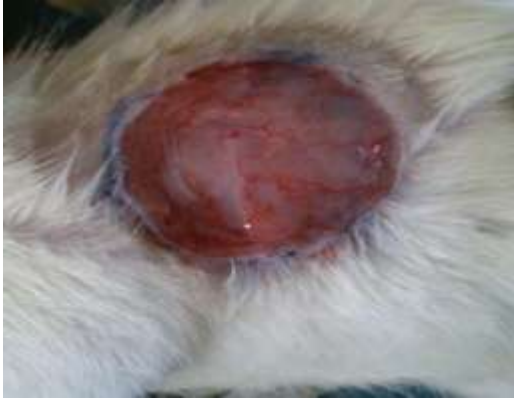

Figure 2: Control 11th day

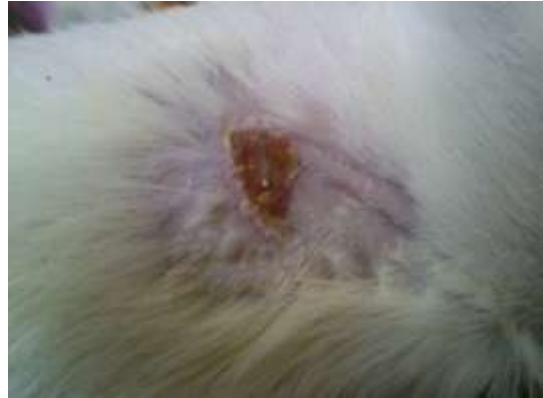

Figure 3: 5% Povidone iodine 0th day

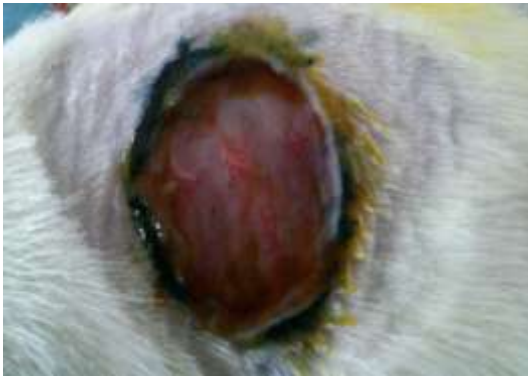

Figure 4: 5% w/w Povidone iodine 11th day

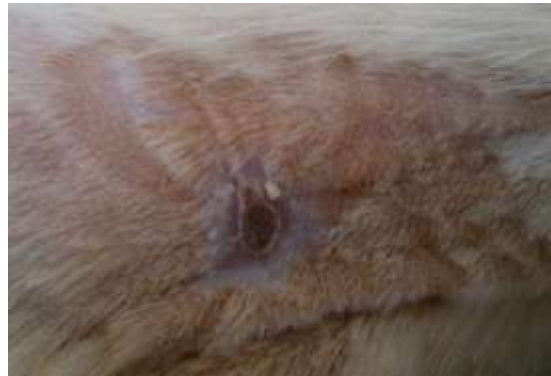

Figure 5: 10% EAEEC extract 0th day

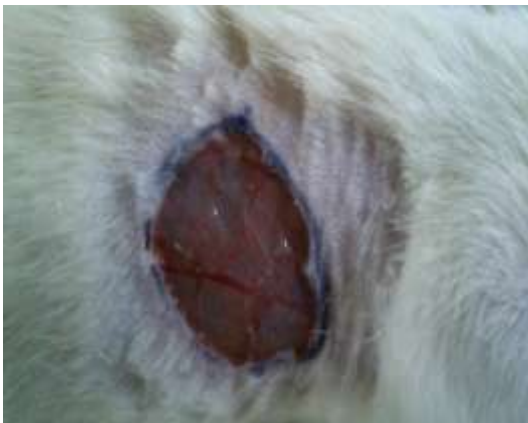

Figure 6: 10% EAEEC extract 11th day

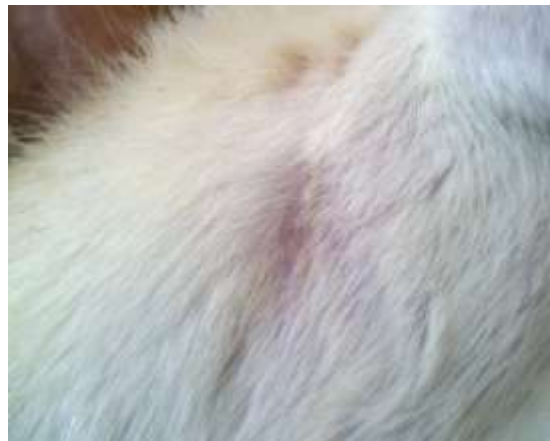

Figure 7. 10 % EEEEC 0th day

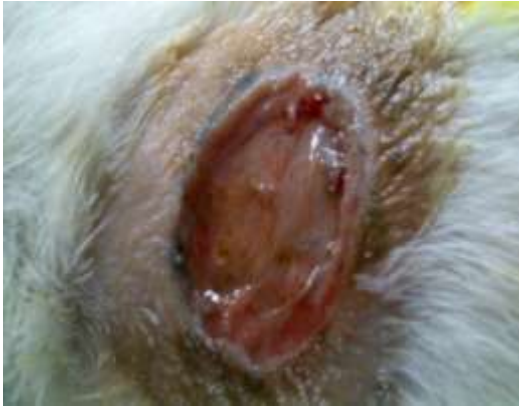
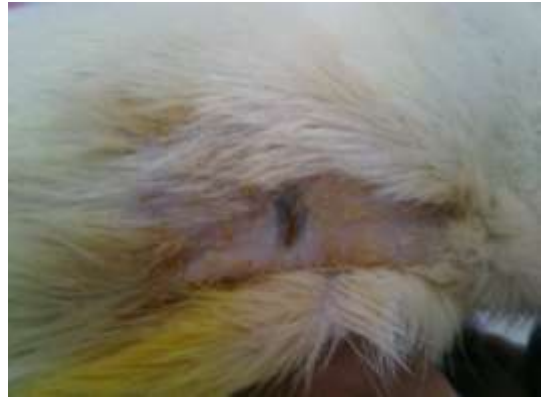
Figure 8. 10%EEEEC 11th day



Effect of extracts of incision wound

Figure 1. Control 0th day

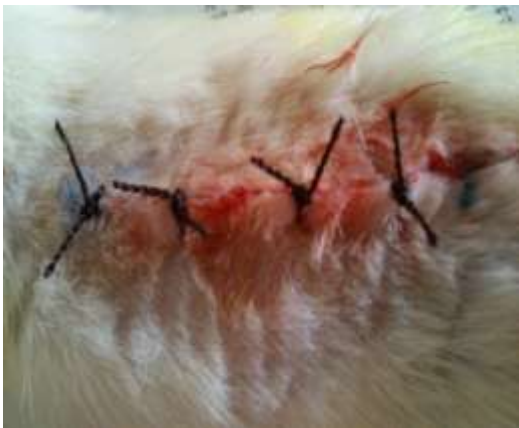

Figure 2. Control 10th day

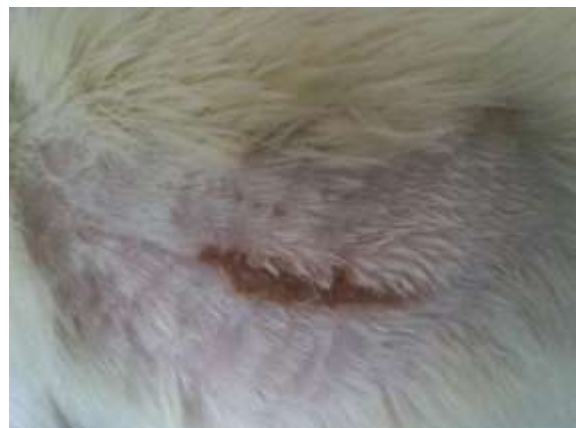

Figure 3. 5% w/w Povidone iodine 0th day

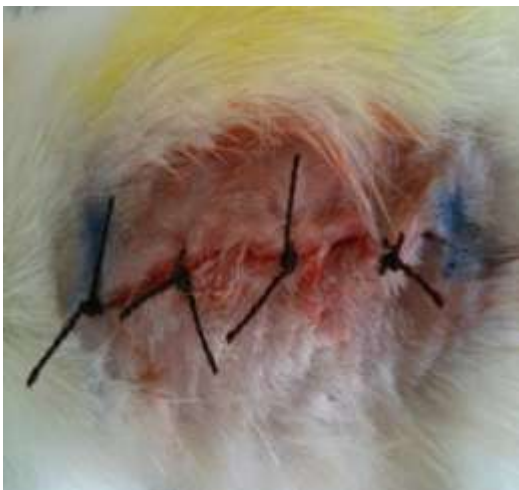

Figure 4. 5% w/w Povidone iodine 10th day

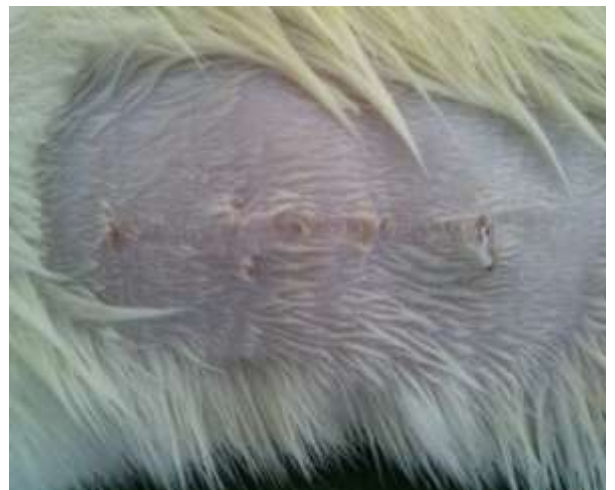

Figure 3. 10%EAEEC extract 0th day

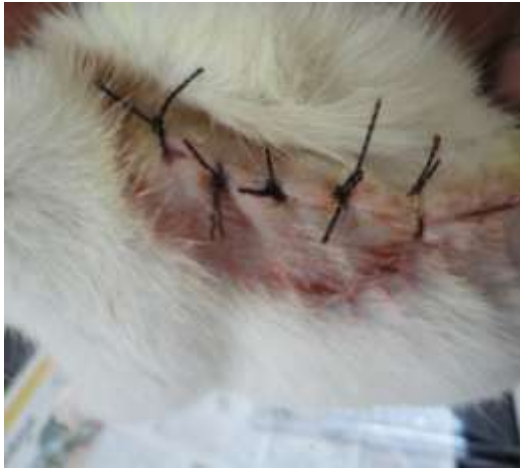

Figure 4. 10%EAEEC extract 10th day

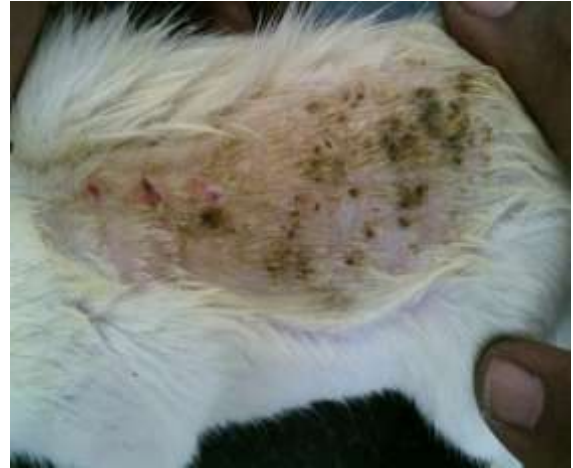

Figure 7. 10 % EEEEC 0th day

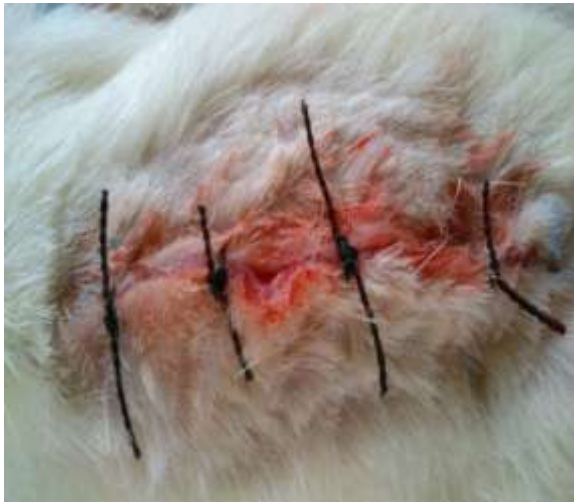
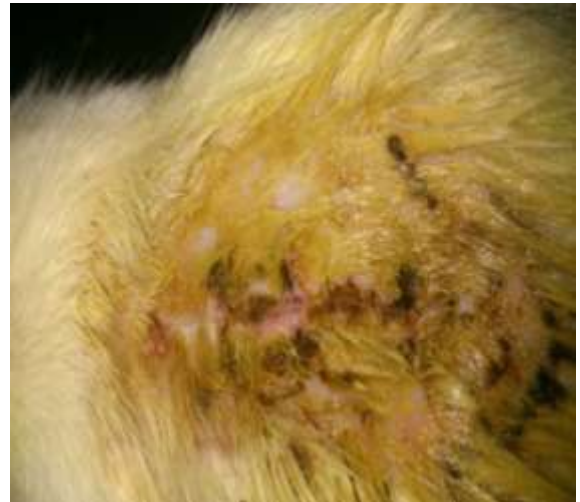
Figure 8. 10%EEEEC 10th day



REFERENCE

1. A Jacqueline, R Hart and Lynn Shumake. Systems to Rate the Strength of Scientific Evidence University of Maryland Medical Center, Glenwood, 2002; 40-45.
2. Andrew Vickers and Catherine Zollman. *BMJ*1999; 319; 1050-1053.
3. Senthil Kumar M, Sripriya R, VijayaRaghavan H and Sehgal P. Wound Healing Potential of Cassia fistula on Infected Albino Rat Model. *J Surg Res*, 2006; 131: 283-289.
4. Meenakshi S, Raghavan G, Nath V, Ajay Kumar SR and Shanta M. Antimicrobial, wound healing and antioxidant activity of *Plagiochasmaappendiculatum*Lehm. et Lind. *J Ethnopharmacol*, 2006; 107: 67-72.
5. Enoch S and John Leaper D. Basic science of wound healing. *Surgery*, 2005; 23: 37 - 42.
6. Suresh Reddy J, Rao PR and Reddy MS. Wound healing effects of *Heliotropiumindicum*, *Plumbagozeylanicum*and *Acalyphaindicain* rats. *J Ethnopharmacol*, 2002; 79: 249-251.
7. Kumar B, Vijayakumar M, Govindarajan R and Pushpangadan P. Ethnopharmacological approaches to wound healing – Exploring medicinal plants of India, *J Ethnopharmacol*, 2007; 114: 103-113.
8. Batish DR, Singh HP, Seita N, Kaur S, Kohli RK. Chemical composition and phytotoxicity of volatile essential oil from intact and fallen leaves of *Eucalyptus citriodora*, *Z Naturforsch C*: 2006;61(7-8), 465-71.
9. K. MadhavaChetty, K. Sivaji, K. TulasiRao. Flowering plants of Chittoor District Andhra Pradesh, India, Published by Students Offset Printers, Tirupathi; first edition 2008:127-128.
10. Kokate CK. In: Practical Pharmacognosy, Preliminary Phytochemical Screening, first ed., VallabhPrakashan, New Delhi, 1986; 111.

Velmurugan and Geetha et al., World J Pharm Sci 2014; 2(1): 62-71

11. OECD Guidelines for the testing of Chemicals revised draft guidelines, Acute Oral Toxicity-Acute Toxic class methods, Revised Document, October 2000: 423.
12. Morton JJ and Malone MH, Evaluation of vulnerary activity by open wound procedure in rats, Arch IntPharmacodynTher, 196: 117-120(1972).
13. Kamath JV, Rana AC and Chowdhury AR, Prohealing effect of Cinnamomumzeylanicum bark, Phytother Res, 17:970-972v(2003).
14. Lowry OH, Rosenbrough NJ, Farr AL and Randall BJ, Protein measurement. J BiolChem, 193:265-275 (1951).
15. Shivananda B. N., Lecley of Carica papaya L. in experimentally induced diabetic rats, Indian J. Exp. Bio., 2007, 45, 743.
16. Senthil M. K., Kirubanandan S. and Sripriya R., Triphala promotes healing of infected full thickness dermal wound, J. Surg. Res., 2008, 22, 89.
17. Ehrlich HP and Hunt HK, Effect of anabolic steroid on tensile strength of a healing wound. Ann Surg, 170:203-208 (1969).
18. Lee KH, Studies on the mechanism of action of salicylates 3. Effect of vitamin A on wound healing retardation of aspirin, J PharmacolSci, 57:1238-1240 (1968).
19. Reddy JS, Rao PR and Reddy MS, Wound healing effects of Helitropiumindicum, Plumbagozeylanicum and Acalyphaindica in rats, J Ethnopharmacol, 79:249-251 (2002).
20. Turner R.A, Inflammatory agent in screening methods of pharmacology, Academic Press, New York, 2nd Edi., 1965, 475.
21. ShilaGurung, NatasaSkalko-Basnet. Wound healing properties of Carica papaya latex in vivo evaluation in mice burn model, Journal of Ethnopharmacology 121 (2009) 338-341.
22. Akkol EK, Koca U, Pesin I, Yilmazer D, Toker G, Yesilada E: Exploring the wound healing activity of Arnebiadensiflora (Nordm.) Ledeb. by in vivo models. J Ethnopharmacol 2009, 124:137-141.
23. Chithra P, Sajithalal BG, Gowri C. Influence of Aloe veraon collagen turnover in healing of dermal wounds in rats. Ind J Exp Biol.1988; 36:896-901.
24. Manjunatha B K Wound healing activity of SolanumviolaceumOrtg. Indian Drugs. 2006; 43: 835.
25. B. S. Nayak, S. Sandiford, and A. Maxwell, "Evaluation of the wound-healing activity of ethanolic extract of *Morindacitrifolia*L. leaf," *Evidence-based Complementary and Alternative Medicine*, vol. 6, no. 3, pp. 351–356, 2009.
26. J. A. S. Zuanazzi and J. A. Montanha, "Flavon´ oides," in *Farmacognosia: Da PlantaaoMedicamento*, Ufrgs, Porto Alegre/Florian´ opolis, Portugal, 2004.
27. S. C. Santos and J. C. P. Mello, "Taninos," in *Farmacognosia: Da PlantaaoMedicamento*, Ufrgs, Porto Alegre/Florian´ opolis, Portugal, 2004.
28. T. Okuda, "Systematics and health effects of chemically distinct tannins in medicinal plants," *Phytochemistry*, vol. 66, no. 17, pp. 2012–2031, 2005.
29. Pesin, U. Koca, H. Keles, and A. E. Kupeli, "Wound healing activity of *Rubus sanctus*Schreber (Rosaceae): preclinical study in animal models," *Evidence-Based Complementary and Alternative Medicine*. In press.
30. Prabu D, Nappinai M, Ponnudurai K, Prabhu K: Evaluation of woundhealing potential of *Pisoniagrاندis* R. Br: A preclinical study in Wistar rats. Int J Low Extrem Wounds 2008, 7:21.
31. Root-Bernstein, R. S. Tannic acid, semipermeable membranes, and burn treatment [letter]. *Lancet* 2:1168; 1982.
32. Hupkens, P.; Boxma, H.; Dokter, J. Tannic acid as a topical agent in burns: historical considerations and implications for new developments. *Burns* 21:57–61; 1995.
33. Choudhary GP: Wound healing activity of the ethanol extract of *Terminaliabellicarica*Roxb. fruits. Nat Prod Rad 2008, 7:19-21.